



PATIENT

Millie Barry

SPECIES

Canine

BREED

Chihuahua

SEX

Female Spayed

AGE

12 years

WEIGHT

8.75lbs

INTERPRETED BY

Maggie Machen
Lamy, DVM
DACVIM (Cardiology)

IMAGING

PERFORMED BY

Pamela Harrigan,
RDCS

HOSPITAL NAME

Mass Veterinary
Specialty Services

REFERRING VET

Dr. Masloski

PRESENTING CLINICAL SIGNS

History: Recheck echo. History chronic valvular disease - Stage B2. Current presentation: Millie has an occasional, but not daily, cough. She is breathing comfortably with a good appetite and activity level. CV/RESP: NSR, grade IV/VI murmur with PMI left apical area radiating to right, PSS, lung fields clear. BP: 140mmHg x 4.

-Current medications: Pimobendan/vetmedin 1.25mg 1 tab twice a day *No sedation.
- Pertinent previous echo findings (3/3/21 MML): LA 2.3 cm; LA:Ao 1.77; LV 2.6 cm; moderate LAE; moderate MR; mild-moderate TR (2.6 m/s).

ECHOCARDIOGRAM FINDINGS

2D, m-mode, color flow and Doppler imaging is available.

Left ventricle: The LV diameter is borderline increased with adequate function. LV wall thicknesses are normal.

Left atrium: The left atrium is mildly dilated.

Mitral valve: The mitral valve is diffusely thickened with significant prolapse into the left atrial lumen. Moderate eccentric mitral regurgitation with a normal velocity.

Aortic valve/Aorta: The aortic valve is normal in morphology and mobility. Normal aortic outflow velocity; laminar flow. No aortic insufficiency.

Right ventricle: Normal right ventricular diameter and morphology indicating no overt evidence of pulmonary arterial hypertension.

Right atrium: Normal RA dimension.

Tricuspid valve: The tricuspid valve appears mildly thickened with mild tricuspid regurgitation. Normal velocity.

Pulmonic valve/Pulmonary artery: The pulmonic valve is normal in morphology and mobility. No pulmonic insufficiency. Normal RVOT velocity; laminar flow.

Pericardium/other: No pericardial or pleural effusion noted. No obvious cardiac masses.

Heart rhythm: ECG reveals a sinus rhythm with an average HR of 170bpm.

2-Dimensional Measurements

Ao diam (cm)	1.5
LA diam (cm)	1.9
LA:Ao (Swe)	1.5
IVS thickness (cm)	0.5
LVID diastole (cm)	2.4
PW thickness (cm)	0.5
LVID systole (cm)	1.2
FS (%)	50

Doppler Measurements

PV Vmax (m/s)	0.7
AoV Vmax (m/s)	1.0
MR Vmax (m/s)	5.5
TR Vmax (m/s)	2.5
TR PG (mmHg)	25

INTERPRETATION OF THE FINDINGS

Chronic degenerative valve disease persists with evidence of stability. Moderate MR is unchanged; however, the LA is improved likely due to Pimobendan therapy. No additional issues are identified such as pulmonary hypertension.

INVOICE

20818

DATE

8/31/21

Given these findings, no additional medications are indicated. Continued assessment of progression in the future will help predict long term outcome, however prognosis remains guarded at this stage (B2).



PATIENT

Millie Barry

SPECIES

Canine

BREED

Chihuahua

SEX

Female Spayed

AGE

12 years

WEIGHT

8.75lbs

INTERPRETED BY

Maggie Machen
Lamy, DVM
DACVIM (Cardiology)

**IMAGING
PERFORMED BY**

Pamela Harrigan,
RDCS

HOSPITAL NAME

Mass Veterinary
Specialty Services

REFERRING VET

Dr. Masloski

INVOICE

20818

DATE

8/31/21

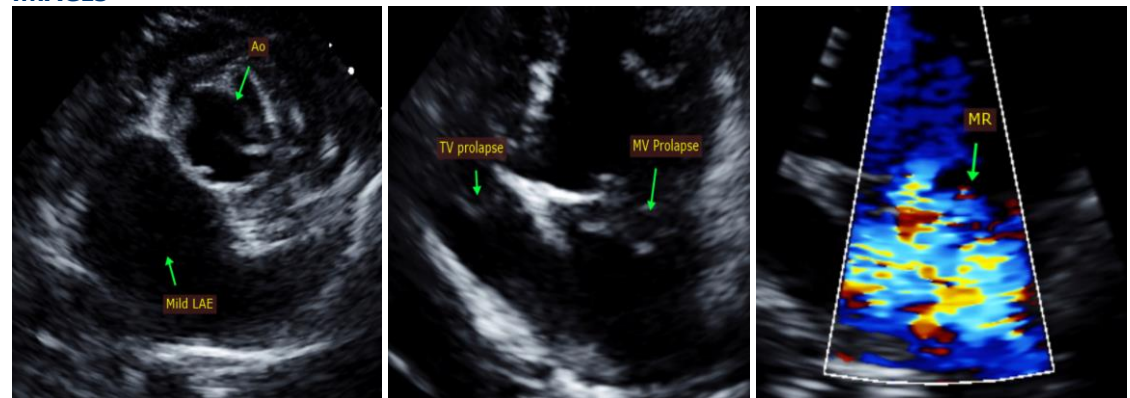
RECOMMENDATIONS

- Continue Pimobendan 0.3mg/kg PO q12h.
- Omega fatty acid supplementation and mild salt restriction may be of some long-term benefit.
- Anesthetic risk is considered mild if needed. Cardiac protective drug choices (opioid/benzodiazepine premedication, propofol or alfaxalone induction, isoflurane gas) are recommended. Pre-oxygenate for 5-10 minutes prior to induction. Monitor for arrhythmias, hypotension, and hypoxia both intra and post-operatively and intervene as necessary. Mild IV fluid restriction is recommended to avoid fluid overload. Avoid heart rate stimulating drugs such as atropine unless clinically indicated.
- Monitor for development of a cough, labored breathing, exercise intolerance or collapse episodes.

PLAN

- Recommend conservative monitoring with a recheck echocardiogram in 6 months, sooner if any development of clinical signs.

IMAGES



The information and recommendations provided are based on the images presented by the referring veterinarian. No evaluation can be communicated regarding pathology that was not visible in the image/video clips provided.

Thank you for this referral. This report was generated using transcription software, and minor dictation errors may be present. If the clinical or image interpretation does not parallel your findings or if I can be of any further assistance, please contact me.

Maggie Machen Lamy, DVM

Diplomate of the American College of Veterinary Internal Medicine (Cardiology)
info@sonopath.com

Echocardiogram performed by: Pamela Harrigan, RDCS

Pet Animal Ultrasound Service (4paus.com)